

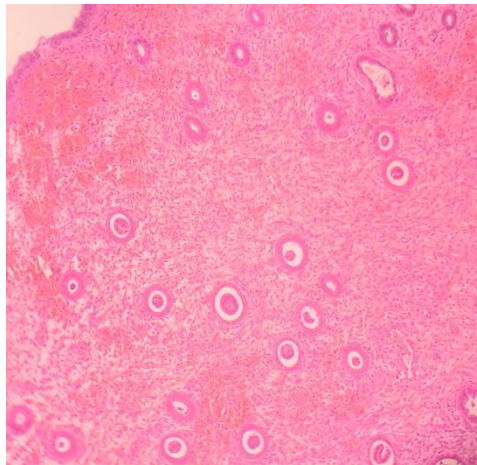
<b>Patient Name</b>	<b>Mrs. SHEELA DEVI</b>	<b>Client Name</b>	Lifeaid Wellness Centre,	<b>Specimen Received</b>	19-Sep-2019
<b>Age/Sex</b>	48 Years/Female		Gurgaon	<b>Specimen Type</b>	Tissue
<b>Patient ID</b>	011909190158			<b>Collection Date</b>	19-Sep-2019
<b>Specimen ID</b>	MOLQ/B-1798/19			<b>Report Date</b>	25-Sep-2019

## SURGICAL PATHOLOGY REPORT

Endometrial polyp and endometrial curetting.

### DIAGNOSIS

## PROLIFERATIVE PHASE WITH ENDOMETRIAL POLYP



#### SPECIMEN

Endometrial polyp and endometrial curetting.

#### GROSS

Received multiple greyish white tissue pieces.

#### Microscopy

1. Section examined shows small endometrial glands with cuboidal lining epithelium with small round nucleus. Stroma shows mononuclear inflammatory cells.
2. Polyp shows lining epithelium with round nucleus.
3. No granuloma and no malignant cells seen.

**Note :** All biopsy specimen will be stored for 15 (fifteen) days, block and slides for 5 (five) years only from the time of receipt at the laboratory. No request, for any of the above, will be entertained after the due date.

#### Reference

- i) Rosai and Ackerman's Surgical Pathology.
- ii) Modern Surgical Pathology.

**Gulshan Yadav, MD**  
Consultant Pathologist