

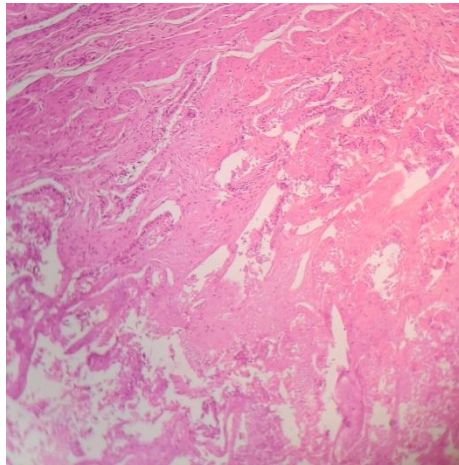
Patient Name	Mrs. SUNITA	Client Name	Chiranjeev Path Lab, Gurgaon	Specimen Received	18-Sep-2019
Age/Sex	45 Years/Female			Specimen Type	Tissue
Patient ID	011909180177			Collection Date	18-Sep-2019
Specimen ID	MOLQ/B-1786/19			Report Date	25-Sep-2019

SURGICAL PATHOLOGY REPORT

Gall Bladder

DIAGNOSIS

CHOLECYSTITIS.



SPECIMEN

Gall Bladder

GROSS

Received 4.6x2.4cm long gall bladder. Cut section shows no stones and wall thickness 0.5 mm.

Microscopy

1. Section examined shows ulcerative mucosa and Rokitansky-Aschoff sinuses (irregularly shaped tubular structures lined by cuboidal lining epithelium with round to oval nucleus) with fibrocollagenous tissue and inflammatory cells (lymphocytes).
2. No granuloma and no malignant cells seen.

Note : All biopsy specimen will be stored for 15 (fifteen) days, block and slides for 5 (five) years only from the time of receipt at the laboratory. No request, for any of the above, will be entertained after the due date.

Reference

- i) Rosai and Ackerman's Surgical Pathology.
- ii) Modern Surgical Pathology.

Gulshan Yadav, MD
Consultant Pathologist