

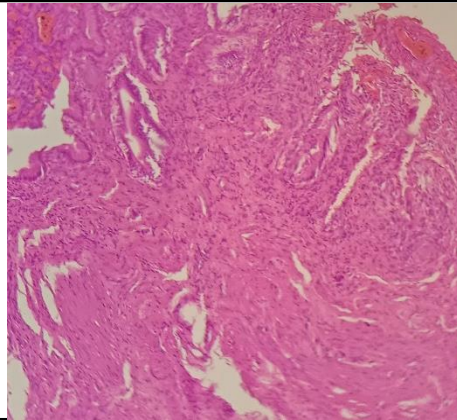
Patient Name	Mrs. GULLO	Client Name	Accurate Path (C), Agra	Specimen Received	19/09/19
Age/Sex	35 Years/Female			Specimen Type	Tissue
Patient ID	011909190002			Collection Date	19/09/19
Specimen ID	MOLQ/B-1788/19			Report Date	24/09/19

SURGICAL PATHOLOGY REPORT

Gall Bladder

DIAGNOSIS

CHOLECYSTITIS AND CHOLELITHIASIS.



SPECIMEN

Gall Bladder

GROSS

Received 7.5x2.8 cm long gall bladder. Cut section shows stones.

Microscopy

Section examined shows ulcerative mucosa and Rokitansky-Aschoff sinuses (irregularly shaped tubular structures lined by cuboidal lining epithelium with round to oval nucleus) with fibro collagenous tissue and inflammatory cells (lymphocytes).

Section also shows normal hepatocytes.

Note : All biopsy specimen will be stored for 15 (fifteen) days, block and slides for 5 (five) years only from the time of receipt at the laboratory. No request, for any of the above, will be entertained after the due date.

Reference

- i) Rosai and Ackerman's Surgical Pathology.
- ii) Modern Surgical Pathology.

Gulshan Yadav, MD
Consultant Pathologist