

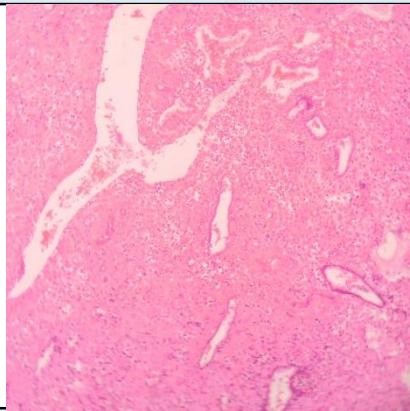
<b>Patient Name</b>	Ms. POONAM	<b>Client Name</b>	Chiranjivi Diagnostic	<b>Specimen Received</b>	16-Sep-19
<b>Age/Sex</b>	27 Years/Female		Jharsa	<b>Specimen Type</b>	Tissue
<b>Patient ID</b>	011909160183			<b>Collection Date</b>	16-Sep-19
<b>Specimen ID</b>	MOLQ/B-1779/19			<b>Report Date</b>	22-Sep-19

## SURGICAL PATHOLOGY REPORT

Endometrium

### DIAGNOSIS

**EXOGENOUS HORMONAL EFFECT**



#### SPECIMEN

Endometrium

#### GROSS

Received multiple grayish white tissue piece.

#### Microscopy

1. Section examined shows small and few cystically dilated endometrial glands with cuboidal lining epithelium having round nucleus.
2. Section also shows pseudodecidual cells.
3. No granuloma seen. No malignant cells seen.

**Note :** All biopsy specimen will be stored for 15 (fifteen)days, block and slides for 5(five) years only from the time of receipt at the laboratory. No request ,for any of the above ,will be entertained after the due date.

#### Reference

- i) Rosai and Ackerman's Surgical Pathology.
- ii) Modern Surgical Pathology.

A handwritten signature in black ink, appearing to read 'Gulshan', written over a light blue rectangular background.

**Gulshan Yadav, MD  
Consultant Pathologist**