

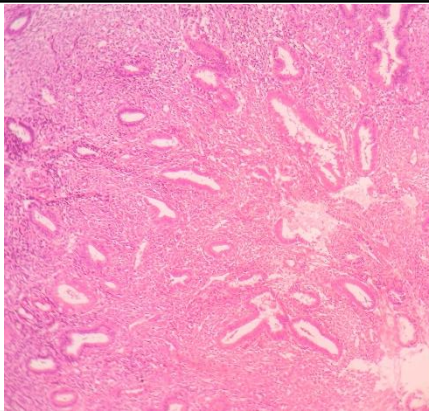
Patient Name	Mrs. KAVITA RANA	Client Name	Path Star Diagnostic	Specimen Received	16-Sep-19
Age/Sex	38 Years/Female			Specimen Type	Tissue
Patient ID	011909160168			Collection Date	16-Sep-19
Specimen ID	MOLQ/B-1778/19			Report Date	22-Sep-19

SURGICAL PATHOLOGY REPORT

Endometrium

DIAGNOSIS

DISORDERED PROLIFERATIVE PHASE WITH SIMPLE HYPERPLASIA WITHOUT ATYPIA



SPECIMEN

Endometrium

GROSS

Received multiple grayish white tissue piece.

Microscopy

1. Section examined shows few occasional cystically dilated and small and tortuous endometrial glands with columnar lining with small round nucleus.
2. Stroma shows mononuclear inflammatory cells, RBCs and fibrin.
3. No granuloma seen. No malignant cells seen.

Note : All biopsy specimen will be stored for 15 (fifteen) days, block and slides for 5 (five) years only from the time of receipt at the laboratory. No request, for any of the above, will be entertained after the due date.

Reference

- i) Rosai and Ackerman's Surgical Pathology.
- ii) Modern Surgical Pathology.

Gulshan Yadav, MD
Consultant Pathologist