

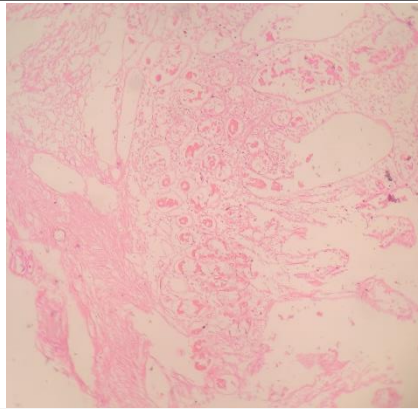
Patient Name	Mr. SATVIR	Client Name	Chiranjivi Diagnostic Jharsa	Specimen Received	14-Sep-19
Age/Sex	42 Years/male	Client Code		Specimen Type	Tissue
Patient ID	011909140272	Ref. Doctor		Collection Date	14-Sep-19
Specimen ID	MOLQ/B-1767/19			Report Date	22-Sep-19

SURGICAL PATHOLOGY REPORT

Stomach-(Polyp?)

DIAGNOSIS

KINDLY, CO-RELATE WITH CLINICAL AND RADIOLOGICAL FINDINGS.



SPECIMEN

Esophagus

GROSS

Received tiny multiple grayish white tissue piece.
(Container Labelled as 1)

Microscopy

Section examined shows autolytic changes with loss of cellular architecture details. There are presence of submucosal glands and stromal cells.

No granuloma seen. No malignant cells seen.

- .Note :** All biopsy specimen will be stored for 15 (fifteen)days, block and slides for 5(five) years only from the time of receipt at the laboratory. No request ,for any of the above ,will be entertained after the due date.

Reference

- Rosai and Ackerman's Surgical Pathology.
- Modern Surgical Pathology.

Gulshan Yadav, MD
Consultant Pathologist