

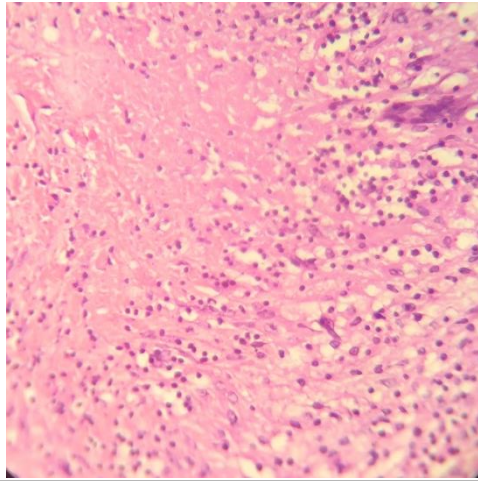
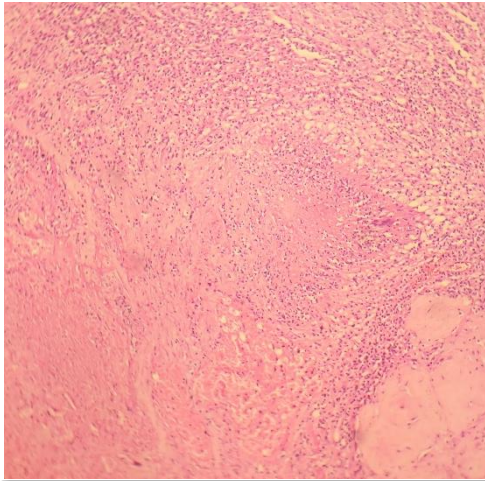
Patient Name	Ms. NEHA	Client Name	Sunrise Diagnostic Centre,	Specimen Received	20-Sep-2019
Age/Sex	20 Years/Female		Agra	Specimen Type	Tissue
Patient ID	011909200012			Collection Date	20-Sep-2019
Specimen ID	MOLQ/B-1794/19			Report Date	20-Sep-2019

SURGICAL PATHOLOGY REPORT

Slide For Second Opinion

DIAGNOSIS

**Granulomatous Reaction
(Tubercular Pathology Strongly Suspicious).**



SPECIMEN

Intestinal Biopsy

GROSS

Received three Hematoxylin and Eosin Stained Slides labeled as K-689-19 A, K-689-19 B, K-689-19 C.

Microscopy

1. Sections examined shows granuloma with central caseous necrosis surrounded by epithelioid cells / histiocytes, lymphocytes and multinucleated giant cells.
2. Section also shows fibrocollagenous tissue, mature adipose cells and blood vessels.
3. No malignant cells seen.

Note : All biopsy specimen will be stored for 15 (fifteen) days, block and slides for 5 (five) years only from the time of receipt at the laboratory. No request ,for any of the above ,will be entertained after the due date.

Reference

- i) Rosai and Ackerman's Surgical Pathology.
- ii) Modern Surgical Pathology.

**Gulshan Yadav, MD
Consultant Pathologist**