

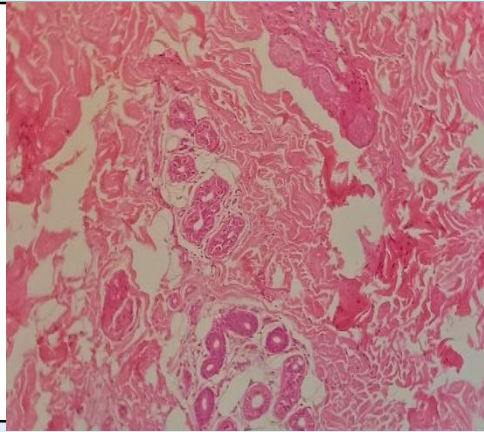
Patient Name	Mrs. REKHA	Client Name	Path Star Diagnostic	Specimen Received	15/09/19
Age/Sex	50 Years/Female			Specimen Type	Tissue
Patient ID	011909150181			Collection Date	15/09/19
Specimen ID	MOLQ/B-1775/19			Report Date	20/09/19

SURGICAL PATHOLOGY REPORT

Soft Tissue Swelling at Back

DIAGNOSIS

Sebaceous Cyst (Back)



SPECIMEN

Soft Tissue Swelling at Back

GROSS

Received 3.8x4.9cm grayish white tissue piece with necrotic material.

Microscopy

Section examined shows squamous lining epithelium with round nucleus with Parakeratosis, fibrocollagenous tissue lymphocytes, plasma cells and polymorphs and mature adipose cells with hair follicle and glands.

No granuloma seen. No malignant cells seen.

Note : All biopsy specimen will be stored for 15 (fifteen)days, block and slides for 5(five) years only from the time of receipt at the laboratory. No request ,for any of the above ,will be entertained after the due date.

Reference

- i) Rosai and Ackerman's Surgical Pathology.
- ii) Modern Surgical Pathology.



Gulshan Yadav, MD
Consultant Pathologist