

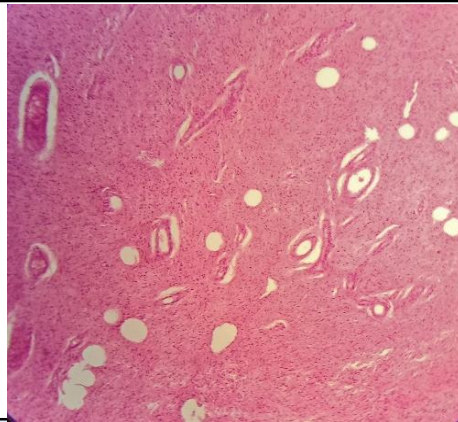
<b>Patient Name</b>	<b>Mr. MALAY CHATURVEDI</b>	<b>Client Name</b>	Lifeaid Wellness Centre	<b>Specimen Received</b>	15/09/19
<b>Age/Sex</b>	53 Years/Male			<b>Specimen Type</b>	Tissue
<b>Patient ID</b>	011909150159			<b>Collection Date</b>	15/09/19
<b>Specimen ID</b>	MOLQ/B-1774/19			<b>Report Date</b>	20/09/19

## SURGICAL PATHOLOGY REPORT

### Soft Nodular Swelling Right Gluteal Area.

#### DIAGNOSIS

#### Benign Mesenchymal Lesion



#### **SPECIMEN**

Soft Nodular Swelling Right Gluteal Area.

#### **GROSS**

Received 4.5x2.2cm long grayish white tissue piece with skin attached ulcerative present.

#### **Microscopy**

Section examined shows mature adipose cells squamous lining epithelium and sebaceous glands. No granuloma and no malignant cells seen.

**Note :** All biopsy specimen will be stored for 15 (fifteen)days, block and slides for 5(five) years only from the time of receipt at the laboratory. No request ,for any of the above ,will be entertained after the due date.

#### **Reference**

- i) Rosai and Ackerman's Surgical Pathology.
- ii) Modern Surgical Pathology.

**Gulshan Yadav, MD**  
Consultant Pathologist