

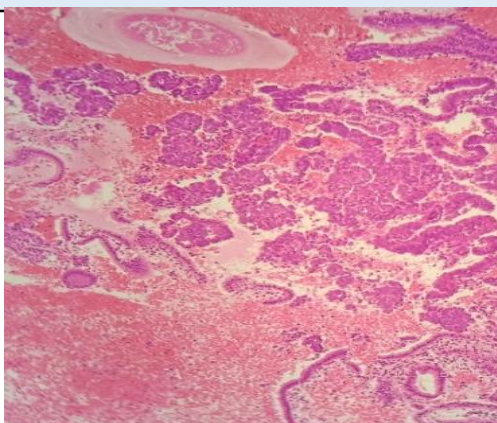
<b>Patient Name</b>	<b>Mrs. SUMITA 38911</b>	<b>Client Name</b>	Pushpanjali Hospital	<b>Specimen Received</b>	14/09/19
<b>Age/Sex</b>	45 Years/Female	(Rewari)		<b>Specimen Type</b>	Tissue
<b>Patient ID</b>	011909140373			<b>Collection Date</b>	14/09/19
<b>Specimen ID</b>	MOLQ/B-1771/19			<b>Report Date</b>	20/09/19

## SURGICAL PATHOLOGY REPORT

### Endometrium

#### DIAGNOSIS

**PROLIFERATIVE PHASE WITH BLEEDING ENDOMETERIUM.**



#### **SPECIMEN**

Endometrium

#### **GROSS**

Section examined shows small endometrial glands with columnar lining with round to oval nucleus. Stroma shows mononuclear inflammatory cells

#### **Microscopy**

Section examined shows small endometrial glands with columnar lining with round to oval nucleus. Stroma shows mononuclear inflammatory cells and RBCs .  
No granuloma seen. No malignant cells seen.

**Note :** All biopsy specimen will be stored for 15 (fifteen)days, block and slides for 5(five) years only from the time of receipt at the laboratory. No request ,for any of the above ,will be entertained after the due date.

#### **Reference**

- i) Rosai and Ackerman's Surgical Pathology.
- ii) Modern Surgical Pathology.

**Gulshan Yadav, MD**  
Consultant Pathologist