

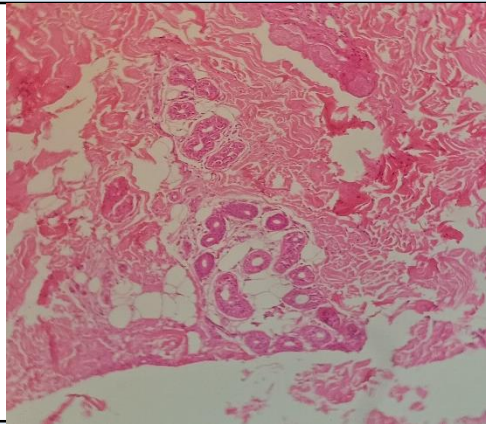
Patient Name	Mr. KULDEEP	Client Name	Polaris Hospital	Specimen Received	14/09/19
Age/Sex	21 Years/Male			Specimen Type	Tissue
Patient ID	011909140073			Collection Date	14/09/19
Specimen ID	MOLQ/B-1765/19			Report Date	20/09/19

SURGICAL PATHOLOGY REPORT

Sebaceous Cyst of Left Shoulder.

DIAGNOSIS

Sebaceous Cyst (Left Shoulder)



SPECIMEN

Sebaceous Cyst of Left Shoulder.

GROSS

Received 1x1.6cm grayish white tissue piece. Cut section shows necrotic material.

Microscopy

Section examined shows squamous lining epithelium with hyperkeratosis and keratin flakes with calcified areas.

No granuloma and no malignant cells seen.

Note : All biopsy specimen will be stored for 15 (fifteen)days, block and slides for 5(five) years only from the time of receipt at the laboratory. No request ,for any of the above ,will be entertained after the due date.

Reference

- i) Rosai and Ackerman's Surgical Pathology.
- ii) Modern Surgical Pathology.



Gulshan Yadav, MD
Consultant Pathologist