

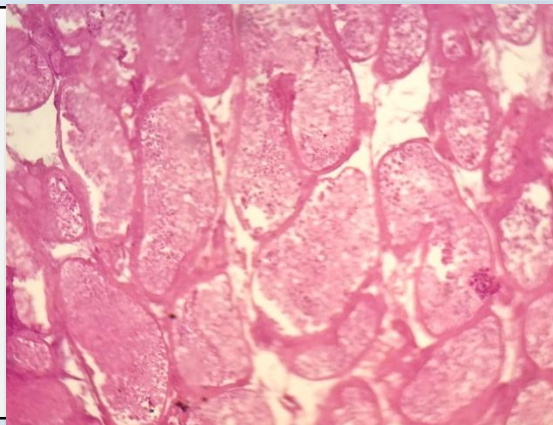
Patient Name	Mr. VIJAY KUMAR 36982	Client Name	Pushpanjali Hospital (Rewari)	Specimen Received	11-Sep-2019
Age/Sex	44 Years/Male			Specimen Type	Tissue
Patient ID	011909110198			Collection Date	11-Sep-2019
Specimen ID	MOLQ/B-1736-19			Report Date	18-Sep-2019

SURGICAL PATHOLOGY REPORT

Right Testicular Abscess

DIAGNOSIS

TESTICULAR ABSCESS WITH GRANULATION TISSUE (RIGHT SIDE)



SPECIMEN

Right Testicular Abscess

GROSS

Received 5.3x2.4 cm long testes. Cut section shows 1.8x1.4 cm Necrotic Area, Abscess?

Microscopy

Section examined shows effacement of testicular architecture with presence of polymorphs, pus cells and necrosis, macrophages and large number of blood vessels.

No granuloma seen. No malignant cells seen.

Note : All biopsy specimen will be stored for 15 (fifteen) days, block and slides for 5 (five) years only from the time of receipt at the laboratory. No request, for any of the above, will be entertained after the due date.

Reference

- i) Rosai and Ackerman's Surgical Pathology.
- ii) Modern Surgical Pathology.

Gulshan Yadav, MD
Consultant Pathologist