

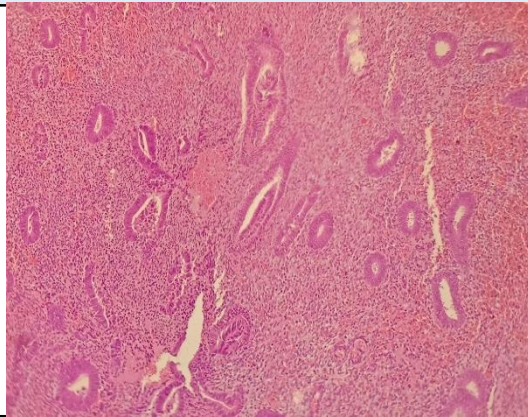
Patient Name	Mrs. RAJ BALA	Client Name	Pushpanjali Hospital (Rewari)	Specimen Received	11-Sep-2019
Age/Sex	48 Years/Female			Specimen Type	Tissue
Patient ID	011909110197			Collection Date	11-Sep-2019
Specimen ID	MOLQ/B-1738/19			Report Date	17-Sep-2019

SURGICAL PATHOLOGY REPORT

Endometrial biopsy.

DIAGNOSIS

Proliferative phase



SPECIMEN

Endometrial biopsy.

GROSS

Received multiple grayish white tissue piece.

Microscopy

Section examined shows scanty cellularity with few endometrial glands with columnar lining epithelium with round to oval nucleus.

Stroma shows mononuclear inflammatory and fibrin. No granuloma and no malignant cells seen.

Note : All biopsy specimen will be stored for 15 (fifteen)days, block and slides for 5(five) years only from the time of receipt at the laboratory. No request ,for any of the above ,will be entertained after the due date.

Reference

- i) Rosai and Ackerman's Surgical Pathology.
- ii) Modern Surgical Pathology.

Gulshan Yadav, MD
Consultant Pathologist