

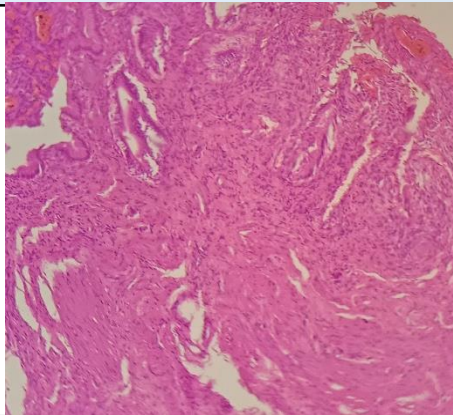
Patient Name	Mr. SURENDER	Client Name	Civil Hospital Sec-10	Specimen Received	11-Sep-2019
Age/Sex	34 Years/Male			Specimen Type	Tissue
Patient ID	011909120187			Collection Date	11-Sep-2019
Specimen ID	MOLQ/B-1743/19			Report Date	18-Sep-2019

SURGICAL PATHOLOGY REPORT

Gall Bladder

DIAGNOSIS

CHOLECYSTITIS AND CHOLELITHIASIS.



SPECIMEN

Gall Bladder

GROSS

Received 10.1x2.8cm long gall bladder. Already Cut Open shows stones. Wall thickness 0.6mm


Microscopy

Section examined shows ulcerative mucosa and Rokitansky-Aschoff sinus (irregularly shaped tubular structures lined by cuboidal lining epithelium with round to oval nucleus) with fibro collagenous tissue and inflammatory cells (lymphocytes).

Note : All biopsy specimen will be stored for 15 (fifteen) days, block and slides for 5 (five) years only from the time of receipt at the laboratory. No request, for any of the above, will be entertained after the due date.

Reference

- i) Rosai and Ackerman's Surgical Pathology.
- ii) Modern Surgical Pathology.



Gulshan Yadav, MD
Consultant Pathologist