

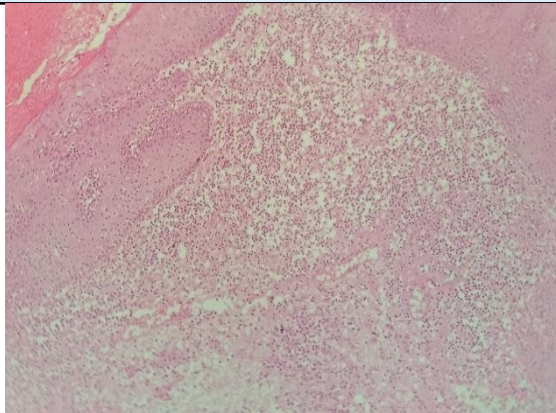
<b>Patient Name</b>	<b>Mrs. REKHA</b>	<b>Client Name</b>	Patient Care Diagnostics,	<b>Specimen Received</b>	11-Sep-2019
<b>Age/Sex</b>	28 Years/Female	Faridabad		<b>Specimen Type</b>	Tissue
<b>Patient ID</b>	011909110295			<b>Collection Date</b>	11-Sep-2019
<b>Specimen ID</b>	MOLQ/B-1739/19			<b>Report Date</b>	18-Sep-2019

## SURGICAL PATHOLOGY REPORT

Uterus with Cervix

### DIAGNOSIS

**CHRONIC CERVICITIS WITH LUTEAL CYST WITH HEMORRHAGIC CYST.**



#### SPECIMEN

Uterus with Cervix

#### GROSS

Received 6.5x4.2 cm uterus with cervix with bilateral adnexa. Ovary size 2x2 cm, 3x2 cm.

#### Microscopy

Section examined shows

- 1) Endometrium with proliferative phase
- 2) Myometrium with muscle bundles
- 3) Cervix with mononuclear inflammatory cells
- 4) Both Ovary show luteal cyst and hemorrhagic cyst.

**Note :** All biopsy specimen will be stored for 15 (fifteen) days, block and slides for 5 (five) years only from the time of receipt at the laboratory. No request, for any of the above, will be entertained after the due date.

#### Reference

- i) Rosai and Ackerman's Surgical Pathology.
- ii) Modern Surgical Pathology.

**Gulshan Yadav, MD**  
Consultant Pathologist