

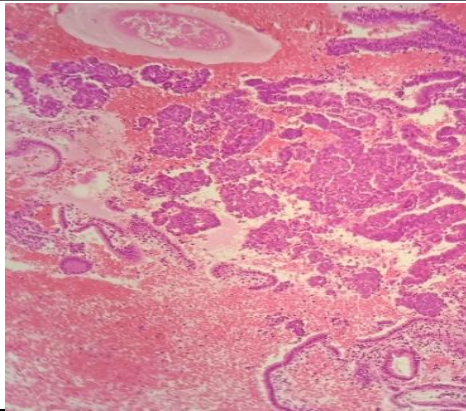
<b>Patient Name</b>	<b>Mrs. ABIDA</b>	<b>Client Name</b>	Polaris Hospital	<b>Specimen Received</b>	11-Sep-2019
<b>Age/Sex</b>	52 Years/Female			<b>Specimen Type</b>	Tissue
<b>Patient ID</b>	011909110207			<b>Collection Date</b>	11-Sep-2019
<b>Specimen ID</b>	MOLQ/B-1737/19			<b>Report Date</b>	18-Sep-2019

## SURGICAL PATHOLOGY REPORT

Endometrial biopsy.

### DIAGNOSIS

**Simple Hyperplasia Without Atypia.**



#### SPECIMEN

Endometrial biopsy.

#### GROSS

Received multiple grayish white tissue piece.

#### Microscopy

Section examined shows small and cystically dilated endometrial glands with columnar lining epithelium with round to oval nucleus. Stroma shows mononuclear inflammatory cells. No granuloma and no malignant cells seen.

**Note :** All biopsy specimen will be stored for 15 (fifteen)days, block and slides for 5(five) years only from the time of receipt at the laboratory. No request ,for any of the above ,will be entertained after the due date.

#### Reference

- i) Rosai and Ackerman's Surgical Pathology.
- ii) Modern Surgical Pathology.

**Gulshan Yadav, MD  
Consultant Pathologist**