

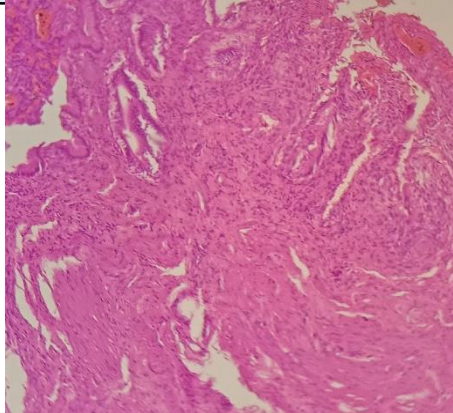
Patient Name	Mr. ABHISHEK	Client Name	Kriti Hospital	Specimen Received	11-Sep-2019
Age/Sex	23 Years/Male			Specimen Type	Tissue
Patient ID	011909110183			Collection Date	11-Sep-2019
Specimen ID	MOLQ/B-1735/19			Report Date	17-Sep-2019

SURGICAL PATHOLOGY REPORT

Gall Bladder

DIAGNOSIS

CHOLECYSTITIS AND CHOLELITHIASIS.



SPECIMEN

Gall Bladder

GROSS

Received 6.5x2cm long gall bladder. Cut section shows tiny stones and wall thickness 0.4mm.

Microscopy

Section examined shows ulcerative mucosa and rokitansky aschoff sinus (irregularly shaped tubular structures lined by cuboidal lining epithelium with round to oval nucleus) with fibro collagenous tissue and inflammatory cells (lymphocytes).

Note : All biopsy specimen will be stored for 15 (fifteen)days, block and slides for 5(five) years only from the time of receipt at the laboratory. No request ,for any of the above ,will be entertained after the due date.

Reference

- i) Rosai and Ackerman's Surgical Pathology.
- ii) Modern Surgical Pathology.

**Gulshan Yadav, MD
Consultant Pathologist**