

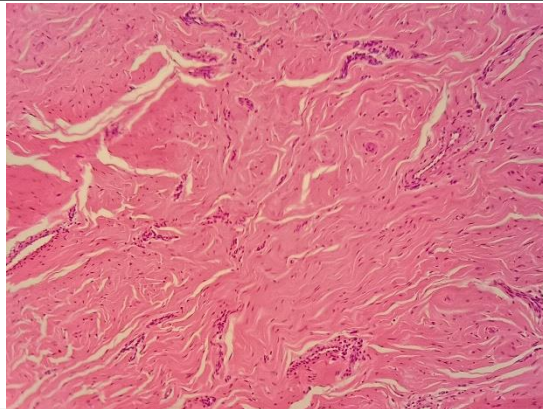
Patient Name	Mrs. SHYAM WATI	Client Name	Kriti Hospital	Specimen Received	11-Sep-2019
Age/Sex	46 Years/Female	Client Code	MOLQ1112P	Specimen Type	Tissue
Patient ID	011909110181	Ref. Doctor		Collection Date	11-Sep-2019
Specimen ID	MOLQ/B-1734/19			Report Date	17-Sep-2019

SURGICAL PATHOLOGY REPORT

Gall Bladder

DIAGNOSIS

CHOLECYSTITIS AND CHOLELITHIASIS.



SPECIMEN

Gall Bladder

GROSS

Received 7.5x2.8cm long gall bladder already cut open with tiny stones wall thickness 0.4mm.

Microscopy

Section examined shows ulcerative mucosa and Rokitansky-Aschoff sinuses (irregularly shaped tubular structures lined by cuboidal lining epithelium with round to oval nucleus) with fibrocollagenous tissue and inflammatory cells (lymphocytes).

Note : All biopsy specimen will be stored for 15 (fifteen) days, block and slides for 5 (five) years only from the time of receipt at the laboratory. No request, for any of the above, will be entertained after the due date.

Reference

- i) Rosai and Ackerman's Surgical Pathology.
- ii) Modern Surgical Pathology.

Gulshan Yadav, MD
Consultant Pathologist