

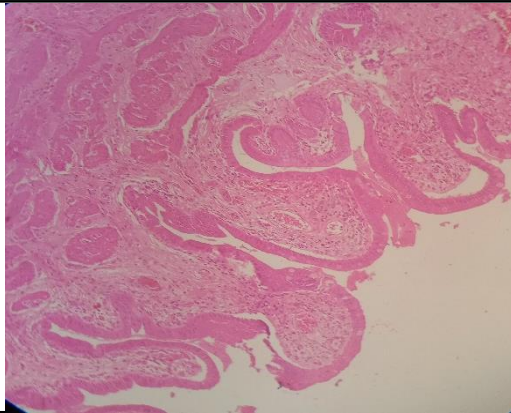
Patient Name	Mrs. BIBHA	Client Name	Care Diagnostics Centre	Specimen Received	10-Sep-2019
Age/Sex	28 Years/Female	Client Code	MolQ1522P	Specimen Type	Tissue
Patient ID	011909100383	Ref. Doctor		Collection Date	10-Sep-2019
Specimen ID	MOLQ/B-1731/19			Report Date	17-Sep-2019

SURGICAL PATHOLOGY REPORT

Gall Bladder

DIAGNOSIS

CHOLECYSTITIS AND CHOLELITHIASIS.



SPECIMEN

Gall Bladder

GROSS

Received 8.9x2.5cm long gall bladder already cut open with stones. wall thickness 0.4 mm.

Microscopy

- Section examined shows ulcerative mucosa and Rokitansky-Aschoff sinuses (irregularly shaped tubular structures lined by cuboidal lining epithelium with round to oval nucleus) with fibrocollagenous tissue and inflammatory cells (lymphocytes).

Note : All biopsy specimen will be stored for 15 (fifteen) days, block and slides for 5 (five) years only from the time of receipt at the laboratory. No request, for any of the above, will be entertained after the due date.

Reference

- Rosai and Ackerman's Surgical Pathology.
- Modern Surgical Pathology.

**Gulshan Yadav, MD
Consultant Pathologist**