

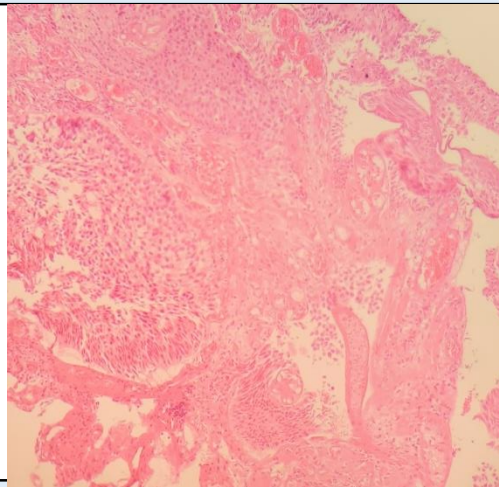
Patient Name	Mrs. ANITA	Client Name	Arban Hospital	Specimen Received	07-Sep-2019
Age/Sex	30 Years/Female			Specimen Type	Tissue
Patient ID	011909070111			Collection Date	07-Sep-2019
Specimen ID	MOLQ/B-1716/19			Report Date	16-Sep-2019

SURGICAL PATHOLOGY REPORT

Right Ovarian Cyst with Tube engulfed inside it.

DIAGNOSIS

DERMOID CYST



SPECIMEN

Right Ovarian Cyst with Tube engulfed inside it.

GROSS

Received multiple grayish white tissue piece measuring 7.6x7.8 cm in aggregate, tubular structure seen in between measuring 3.5x1.2 cm.

Microscopy

Section examined shows tubal lining epithelium with surrounding tissue with inflammatory cells. Ovary shows stromal cells, blood vessels, muscle bundles and cyst lined with columnar lining epithelium.
No granuloma and no malignant cells seen.

Note : All biopsy specimen will be stored for 15 (fifteen)days, block and slides for 5(five) years only from the time of receipt at the laboratory. No request ,for any of the above ,will be entertained after the due date.

Reference

- i) Rosai and Ackerman's Surgical Pathology.
- ii) Modern Surgical Pathology.

Gulshan Yadav, MD
Consultant Pathologist