

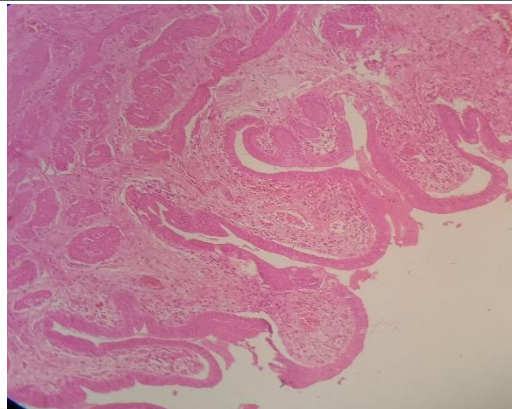
Patient Name	Mr. VEENA BHASIN	Client Name	Pushpanjali Hospital	Specimen Received	07-09-2019
Age/Sex	59 Years/Male	(Rewari)		Specimen Type	Tissue
Patient ID	011909070323			Collection Date	07-09-2019
Specimen ID	MOLQ/B-1724-19			Report Date	12 09 2019

SURGICAL PATHOLOGY REPORT

Gall Bladder

DIAGNOSIS

CHOLECYSTITIS AND CHOLELITHIASIS.



SPECIMEN

Gall Bladder

GROSS

Received 2.6x1.9 CM long gall bladder. Cut section shows tiny stones. Wall Thickness 0.2 mm.

Microscopy

Section examined shows ulcerative mucosa and rokitansky aschoff sinus (irregularly shaped tubular structures lined by cuboidal lining epithelium with round to oval nucleus) with fibro collagenous tissue and inflammatory cells (lymphocytes).

Note : All biopsy specimen will be stored for 15 (fifteen)days, block and slides for 5(five) years only from the time of receipt at the laboratory. No request ,for any of the above ,will be entertained after the due date.

Reference

- i) Rosai and Ackerman's Surgical Pathology.
- ii) Modern Surgical Pathology.

Gulshan Yadav, MD
Consultant Pathologist