

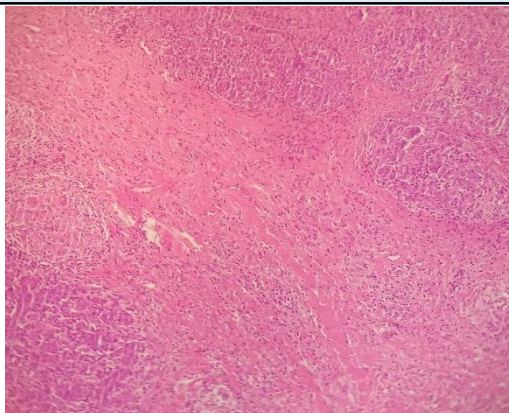
Patient Name	Mrs. SAPNA SINGH	Client Name	Civil Hospital Sec-10	Specimen Received	07-09-2019
Age/Sex	30 Years/Female			Specimen Type	Tissue
Patient ID	011909070219			Collection Date	07-09-2019
Specimen ID	MOLQ/B-1719/19			Report Date	12 09 2019

SURGICAL PATHOLOGY REPORT

Breast abscess (Side not mentioned)

DIAGNOSIS

Infective lesion.



SPECIMEN

Right Ovarian
Cyst with Tube engulfed inside it.

GROSS

Received 4x3 cm grayish white tissue piece.

Microscopy

Section examined shows ductal cells with cuboidal lining epithelium and round nucleus with mild anisonucleosis surrounded by large number of inflammatory cells(lymphocytes, polymorphs). Section also shows surrounding stromal cells.
No granuloma and no malignant cells seen.

Note : All biopsy specimen will be stored for 15 (fifteen)days, block and slides for 5(five) years only from the time of receipt at the laboratory. No request ,for any of the above ,will be entertained after the due date.

Reference

- i) Rosai and Ackerman's Surgical Pathology.
- ii) Modern Surgical Pathology.

Gulshan Yadav, MD
Consultant Pathologist