

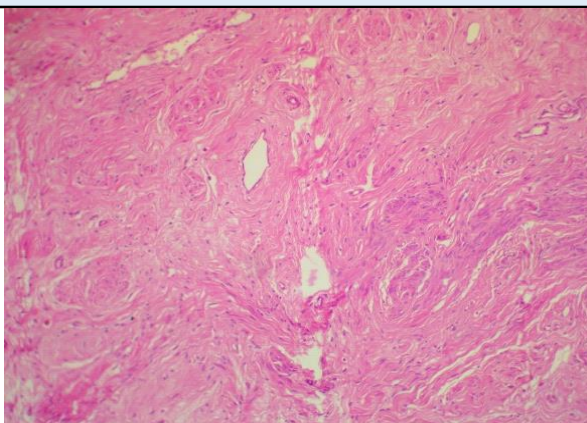
<b>Patient Name</b>	<b>Mrs. SUMAN 33821</b>	<b>Client Name</b>	Pushpanjali Hospital	<b>Specimen Received</b>	04/09/19
<b>Age/Sex</b>	38 Years/Female	<b>(Rewari)</b>		<b>Specimen Type</b>	Tissue
<b>Patient ID</b>	011909040358			<b>Collection Date</b>	04/09/19
<b>Specimen ID</b>	MOLQ/B-1703/19			<b>Report Date</b>	10/09/19

## SURGICAL PATHOLOGY REPORT

### Uterus with Cervix

#### DIAGNOSIS

#### Leiomyoma



#### **SPECIMEN**

Uterus with Cervix

#### **GROSS**

Received 8.6x5.7 cm uterus with cervix with bilateral tube size 0.5x0.5 cm, 1.7x1.2 cm tube shows Paratubal cyst.

#### **Microscopy**

Section examined shows

- 1) Endometrium with proliferative phase
- 2) Myometrium with adenomyosis.
- 3) Cervix with mononuclear inflammatory cells
- 4) Bilateral tubes unremarkable with Paratubal cyst.
- 5) Fibroid with interlacing muscle bundles.

**Note :** All biopsy specimen will be stored for 15 (fifteen) days, block and slides for 5 (five) years only from the time of receipt at the laboratory. No request, for any of the above, will be entertained after the due date.

#### **Reference**

- i) Rosai and Ackerman's Surgical Pathology.
- ii) Modern Surgical Pathology.

**Gulshan Yadav, MD**  
Consultant Pathologist