

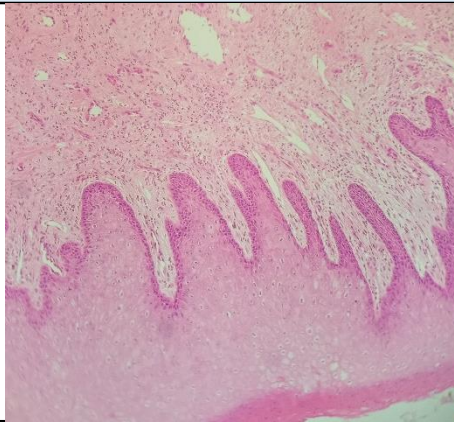
Patient Name	Mrs. BHAGWANTI	Client Name	Health Point Diagnostics	Specimen Received	31/08/19
Age/Sex	45 Years/Female			Specimen Type	Tissue
Patient ID	011908310161			Collection Date	31/08/19
Specimen ID	MOLQ/B-1674/19			Report Date	09/09/19

SURGICAL PATHOLOGY REPORT

Anal Track

DIAGNOSIS

Non-Specific Inflammation with Hemorrhoids.



SPECIMEN

Anal Track

GROSS

Received 1.1x1.2 cm grayish white tissue piece.

Microscopy

Section examined shows squamous lining epithelium with round nucleus deeper tissue shows fibro collagenous tissue and large number of blood vessels and inflammatory cells(lymphocytes, plasma cells).

No granuloma and no malignant cells seen.

Note : All biopsy specimen will be stored for 15 (fifteen)days, block and slides for 5(five) years only from the time of receipt at the laboratory. No request ,for any of the above ,will be entertained after the due date.

Reference

- i) Rosai and Ackerman's Surgical Pathology.
- ii) Modern Surgical Pathology.

Gulshan Yadav, MD
Consultant Pathologist