

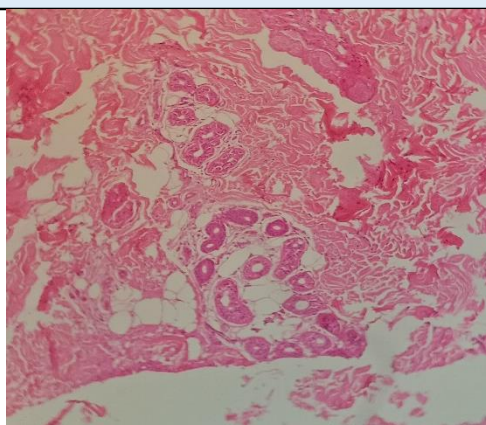
<b>Patient Name</b>	VIKAS	<b>Client Name</b>	Expert Healthcare Centre	<b>Specimen Received</b>	26/08/19
<b>Age/Sex</b>	35 YRS/M			<b>Specimen Type</b>	Tissue
<b>Patient ID</b>	011908260017			<b>Collection Date</b>	26/08/19
<b>Specimen ID</b>	MOLQ/B-1630/19			<b>Report Date</b>	02/09/19

## SURGICAL PATHOLOGY REPORT

### Sebaceous cyst

#### DIAGNOSIS

**Infected sebaceous cyst.**



#### **SPECIMEN**

Sebaceous cyst

#### **GROSS**

Received 4.4x3.6cm grayish white tissue piece with skin attached cut section shows necrotic area.

#### **Microscopy**

Section examined shows squamous lining epithelium with round nucleus with Parakeratosis, fibrocollagenous tissue lymphocytes, plasma cells and polymorphs and mature adipose cells and hair follicle and glands with multinucleated giant cells.

**Note :** All biopsy specimen will be stored for 15 (fifteen)days, block and slides for 5(five) years only from the time of receipt at the laboratory. No request ,for any of the above ,will be entertained after the due date.

#### **Reference**

- i) Rosai and Ackerman's Surgical Pathology.
- ii) Modern Surgical Pathology.

**Gulshan Yadav, MD**  
Consultant Pathologist