

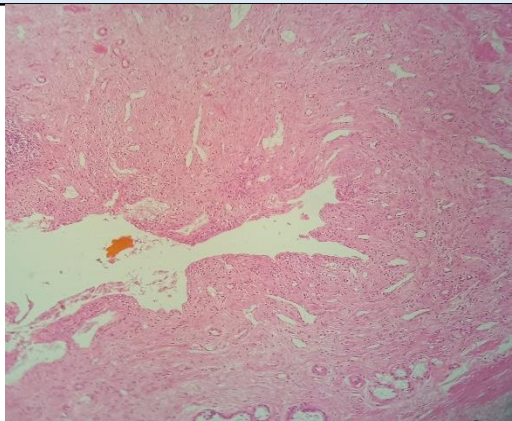
<b>Patient Name</b>	<b>Mrs. MUNNI DEVI</b>	<b>Client Name</b>	Care Diagnostics Centre	<b>Specimen Received</b>	02/09/19
<b>Age/Sex</b>	65 Years/Female			<b>Specimen Type</b>	Tissue
<b>Patient ID</b>	011909020175			<b>Collection Date</b>	02/09/19
<b>Specimen ID</b>	MOLQ/B-1683/19			<b>Report Date</b>	07/09/19

## SURGICAL PATHOLOGY REPORT

### Gall Bladder

#### DIAGNOSIS

**CHOLECYSTITIS AND CHOLELITHIASIS.**



#### **SPECIMEN**

Gall Bladder

#### **GROSS**

Received 6.8x2.8cm long gall bladder already cut open with stones. Wall Thickness 0.5 mm.


#### **Microscopy**

Section examined shows ulcerative mucosa and Rokitansky-Aschoff sinuses (irregularly shaped tubular structures lined by cuboidal lining epithelium with round to oval nucleus) with fibrocollagenous tissue and inflammatory cells (lymphocytes).

**Note :** All biopsy specimen will be stored for 15 (fifteen) days, block and slides for 5 (five) years only from the time of receipt at the laboratory. No request, for any of the above, will be entertained after the due date.

#### **Reference**

- i) Rosai and Ackerman's Surgical Pathology.
- ii) Modern Surgical Pathology.

  
**Gulshan Yadav, MD**  
**Consultant Pathologist**