

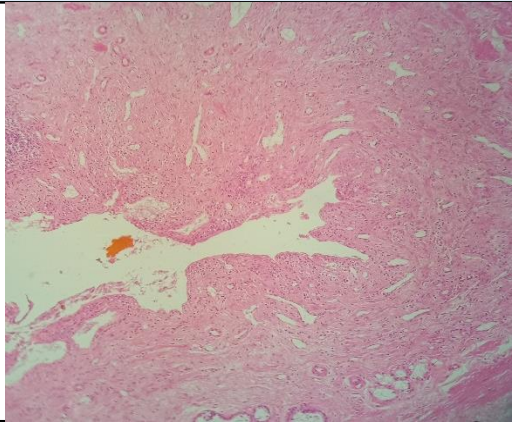
Patient Name	Mr. MITHAN LAL	Client Name	Lifeaid Wellness Centre	Specimen Received	31/08/19
Age/Sex	45 Years/Male			Specimen Type	Tissue
Patient ID	011908310375			Collection Date	31/08/19
Specimen ID	MOLQ/B-1679/19			Report Date	06/09/19

SURGICAL PATHOLOGY REPORT

Gall Bladder

DIAGNOSIS

CHOLECYSTITIS



SPECIMEN

Gall Bladder

GROSS

Received 4.3x2.1cm long gall bladder. Cut section shows no stones.


Microscopy

Section examined shows ulcerative mucosa and Rokitansky-Aschoff sinuses (irregularly shaped tubular structures lined by cuboidal lining epithelium with round to oval nucleus) with fibrocollagenous tissue and inflammatory cells (lymphocytes).

Note : All biopsy specimen will be stored for 15 (fifteen) days, block and slides for 5 (five) years only from the time of receipt at the laboratory. No request, for any of the above, will be entertained after the due date.

Reference

- i) Rosai and Ackerman's Surgical Pathology.
- ii) Modern Surgical Pathology.


Gulshan Yadav, MD
Consultant Pathologist