

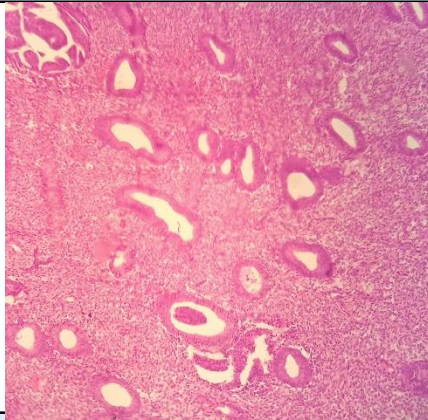
| | | | | | |
|---------------------|--------------------|--------------------|-------------------------|--------------------------|----------|
| Patient Name | Mrs. VINITA | Client Name | Lifeaid Wellness Centre | Specimen Received | 29/08/19 |
| Age/Sex | 46 Years/Female | | | Specimen Type | Tissue |
| Patient ID | 011908290226 | | | Collection Date | 29/08/19 |
| Specimen ID | MOLQ/B-1660/19 | | | Report Date | 04/09/19 |

SURGICAL PATHOLOGY REPORT

Polypectomy and Endometrial Curettings in same container

DIAGNOSIS

Endometrial Polyp with Proliferative Phase .



SPECIMEN

Polypectomy and Endometrial Curettings
in same container

GROSS

Received multiple grayish white tissue piece.

Microscopy

Section examined shows lining epithelium with large number of mononuclear inflammatory cells with small and few cystically dilated endometrial glands having cuboidal lining epithelium having round to oval nucleus.

No granuloma and no malignant cells seen.

Note : All biopsy specimen will be stored for 15 (fifteen)days, block and slides for 5(five) years only from the time of receipt at the laboratory. No request ,for any of the above ,will be entertained after the due date.

Reference

- i) Rosai and Ackerman's Surgical Pathology.
- ii) Modern Surgical Pathology.

Gulshan Yadav, MD
Consultant Pathologist