

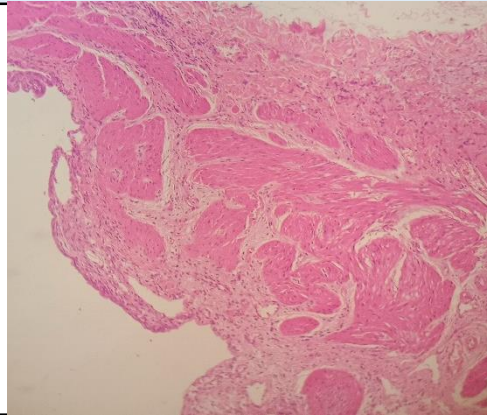
<b>Patient Name</b>	<b>Mrs. RANI</b>	<b>Client Name</b>	Lifeaid Wellness Centre	<b>Specimen Received</b>	29/08/19
<b>Age/Sex</b>	34 Years/Female			<b>Specimen Type</b>	Tissue
<b>Patient ID</b>	011908290217			<b>Collection Date</b>	29/08/19
<b>Specimen ID</b>	MOLQ/B-1666/19			<b>Report Date</b>	04/09/19

## SURGICAL PATHOLOGY REPORT

### Gall Bladder

#### DIAGNOSIS

#### CHOLECYSTITIS AND CHOLELITHIASIS.



#### **SPECIMEN**

Gall Bladder

#### **GROSS**

Received 8.7x4cm long gall bladder already cut open with stones.

#### **Microscopy**

Section examined shows ulcerative mucosa and Rokitansky-Aschoff sinuses (irregularly shaped tubular structures lined by cuboidal lining epithelium with round to oval nucleus) with fibrocollagenous tissue and inflammatory cells (lymphocytes).

**Note :** All biopsy specimen will be stored for 15 (fifteen) days, block and slides for 5 (five) years only from the time of receipt at the laboratory. No request, for any of the above, will be entertained after the due date.

#### **Reference**

- i) Rosai and Ackerman's Surgical Pathology.
- ii) Modern Surgical Pathology.

**Gulshan Yadav, MD**  
Consultant Pathologist