

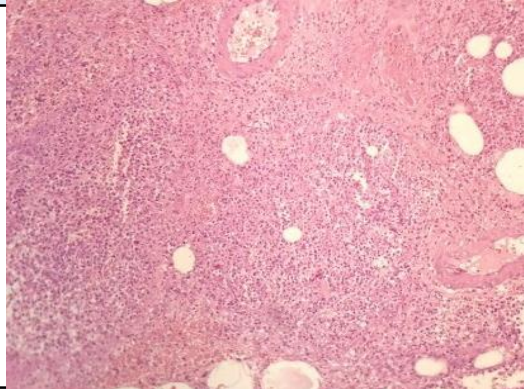
Patient Name	Mr. SACHIN	Client Name	Sona Devi Hospital	Specimen Received	29-Aug-2019
Age/Sex	25 Years/Male			Specimen Type	Tissue
Patient ID	011908290178			Collection Date	29-Aug-2019
Specimen ID	MOLQ/B-1662/19			Report Date	04-Sep-2019

SURGICAL PATHOLOGY REPORT

Appendix

DIAGNOSIS

ACUTE APPENDICITIS



SPECIMEN

Appendix

GROSS

Received 5.3x1.4cm long appendix. Cut section shows feco-lith.

Microscopy

Section examined shows lymphoid follicles with ulcerative mucosa. Deeper tissue shows inflammatory cells (polymorphs and lymphocytes). No granuloma seen. No malignant cells seen.

Note : All biopsy specimen will be stored for 15 (fifteen)days, block and slides for 5(five) years only from the time of receipt at the laboratory. No request ,for any of the above ,will be entertained after the due date.

Reference

- i) Rosai and Ackerman's Surgical Pathology.
- ii) Modern Surgical Pathology.

Gulshan Yadav, MD
Consultant Pathologist