

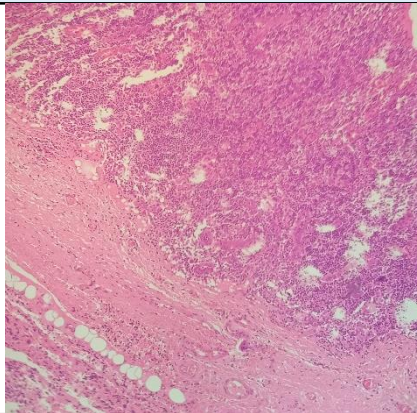
Patient Name	Mr. KALSOM	Client Name	Global Diagnostic Center, Tauru	Specimen Received	26-08-2019
Age/Sex	25 Years/Male			Specimen Type	Tissue
Patient ID	011908260198			Collection Date	26-08-2019
Specimen ID	MOLQ/B-1633/19			Report Date	03-08-2019

SURGICAL PATHOLOGY REPORT

Extra growth in left axillary region.

DIAGNOSIS

Reactive lymphadenitis with histiocytes.



SPECIMEN

Extra growth in left axillary region.

GROSS

Received two greyish white tissue piece measuring 1x1c 2x8cm.

Microscopy

Section examined shows

Capsule with preserved lymphoid architecture with lymphoid follicle having lymphocytes, centrocytes, centroblasts and histiocytes. No well-formed granuloma and no malignant cells seen.

Note : All biopsy specimen will be stored for 15 (fifteen)days, block and slides for 5(five) years only from the time of receipt at the laboratory. No request ,for any of the above ,will be entertained after the due date.

Reference

- i) Rosai and Ackerman's Surgical Pathology.
- ii) Modern Surgical Pathology.

Gulshan Yadav, MD
Consultant Pathologist