

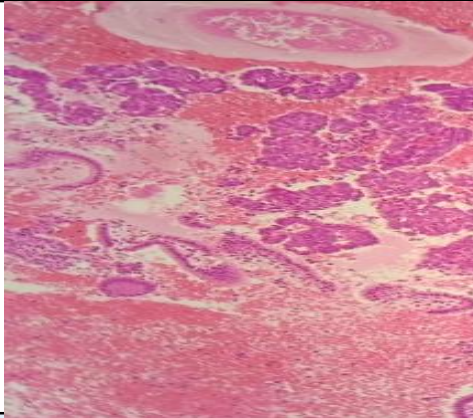
Patient Name	Mrs. SANTRA	Client Name	Pushpanjali Hospital	Specimen Received	23/08/19
Age/Sex	60 Years/Female	(Rewari)		Specimen Type	Tissue
Patient ID	011908230275			Collection Date	23/08/19
Specimen ID	MOLQ/B-1612/19(1)			Report Date	03/09/19

SURGICAL PATHOLOGY REPORT

Endometrium

DIAGNOSIS

Kindly Co-relate Clinically and Radiologically.
Deeper Biopsy for confirmed diagnostic.



SPECIMEN

Endometrium

GROSS

Received multiple grayish white tissue piece.

Microscopy

Paucicellular section examined shows tortuous endometrial glands cuboidal lining epithelium round to oval nucleus with mild anisonucleosis. Smear also shows inflammatory cells and RBCs. No granuloma and no malignant cells seen.

Note : All biopsy specimen will be stored for 15 (fifteen)days, block and slides for 5(five) years only from the time of receipt at the laboratory. No request ,for any of the above ,will be entertained after the due date.

Reference

- i) Rosai and Ackerman's Surgical Pathology.
- ii) Modern Surgical Pathology.

Gulshan Yadav, MD
Consultant Pathologist