

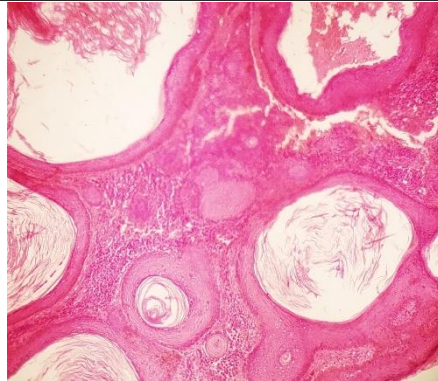
Patient Name	Mrs. BIMLA SHARMA	Client Name	Vedic Hospital	Specimen Received	23-Aug-2019
Age/Sex	67 Years/Female	Client Code	M olQ1492CM	Specimen Type	Tissue
Patient ID	011908230230	Ref. Doctor		Collection Date	23-Aug-2019
Specimen ID	MOLQ/B-1609/19			Report Date	03-Sep-2019

SURGICAL PATHOLOGY REPORT

Right cheek swelling

DIAGNOSIS

HYPERKERATOTIC LESION WITH ACUTE ON CHRONIC INFLAMMATION
IHC CYTOKERATIN FOR ANY MITOTIC ACTIVITY.



SPECIMEN

Right cheek swelling

GROSS

Received multiple grayish white tissue piece irregular shaped and regular margin.

Microscopy

- Section examined shows squamous lining epithelium with hyperkeratosis, large number of mononuclear inflammatory cells(polymorphs) blood vessels, histiocytes, multinucleated giant cells.

Note : All biopsy specimen will be stored for 15 (fifteen)days, block and slides for 5(five) years only from the time of receipt at the laboratory. No request ,for any of the above ,will be entertained after the due date.

Reference

- Rosai and Ackerman's Surgical Pathology.
- Modern Surgical Pathology.

Tina Bhardwaj, MDS
Consultant Oral Pathologist

Gulshan Yadav, MD
Consultant Pathologist