

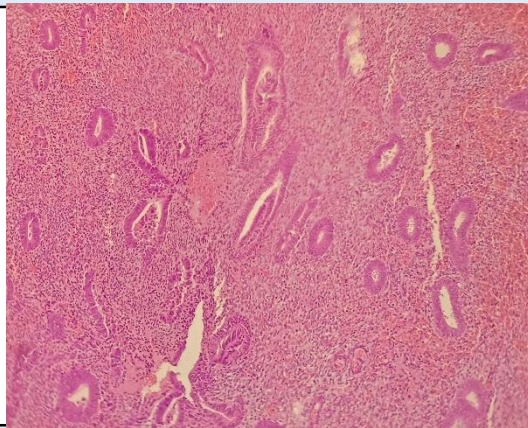
Patient Name	Mrs. POOJA	Client Name	Lalita Memorial Hospital	Specimen Received	28/08/19
Age/Sex	28 Years/Female		Pvt. Ltd. (Rewari)	Specimen Type	Tissue
Patient ID	011908280356			Collection Date	28/08/19
Specimen ID	MOLQ/B-1649/19			Report Date	02/09/19

SURGICAL PATHOLOGY REPORT

Endometrium

DIAGNOSIS

PROLIFERATIVE PHASE



SPECIMEN

Endometrium

GROSS

Received 1.9x0.8cm grayish white tissue piece in aggregate .

Microscopy

Section examined shows small endometrial glands with columnar lining epithelium with round to oval nucleus with squamous metaplasia. Stroma shows mononuclear inflammatory cells.

Note : All biopsy specimen will be stored for 15 (fifteen)days, block and slides for 5(five) years only from the time of receipt at the laboratory. No request ,for any of the above ,will be entertained after the due date.

Reference

- i) Rosai and Ackerman's Surgical Pathology.
- ii) Modern Surgical Pathology.

Gulshan Yadav, MD
Consultant Pathologist