

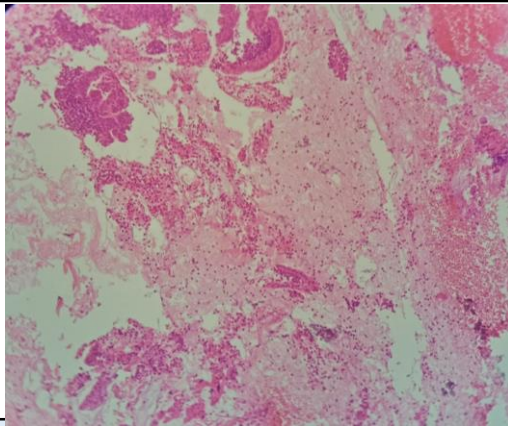
Patient Name	Mrs. SUNITA CHUGH	Client Name	SBS Diagnostic Centre	Specimen Received	28/08/19
Age/Sex	48 Years/Female			Specimen Type	Tissue
Patient ID	011908280240			Collection Date	28/08/19
Specimen ID	MOLQ/B-1646/19			Report Date	02/09/19

SURGICAL PATHOLOGY REPORT

Endometrium

DIAGNOSIS

Disordered proliferative phase.



SPECIMEN

Endometrium

GROSS

Received multiple grayish white tissue piece.

Microscopy

Section examined shows small endometrial glands with columnar lining epithelium round to oval nucleus. Stroma shows mononuclear inflammatory cells seen. No granuloma and no malignant cells seen.

Note : All biopsy specimen will be stored for 15 (fifteen)days, block and slides for 5(five) years only from the time of receipt at the laboratory. No request ,for any of the above ,will be entertained after the due date.

Reference

- i) Rosai and Ackerman's Surgical Pathology.
- ii) Modern Surgical Pathology.

Gulshan Yadav, MD
Consultant Pathologist