

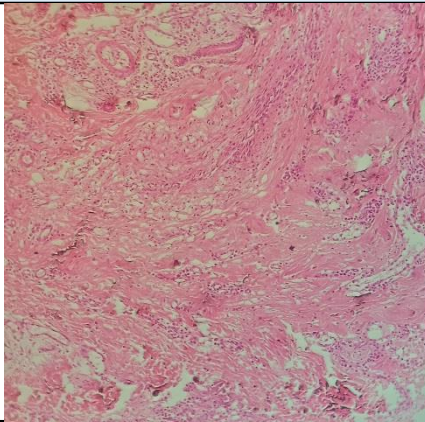
| | | | | | |
|---------------------|--------------------|--------------------|-------------------|--------------------------|----------|
| Patient Name | Mr. SANDEEP | Client Name | Ashtha Path Lab-B | Specimen Received | 26/08/19 |
| Age/Sex | 20 Years/Male | | | Specimen Type | Tissue |
| Patient ID | 011908260188 | | | Collection Date | 26/08/19 |
| Specimen ID | MOLQ/B-1632/19 | | | Report Date | 02/09/19 |

SURGICAL PATHOLOGY REPORT

Pilonidal sinus with surrounding tissue

DIAGNOSIS

Chronic non specific inflammation.



SPECIMEN

Pilonidal sinus with surrounding tissue

GROSS

Received multiple grayish white tissue piece, 3.4x2.8 cm in aggregate.

Microscopy

Section examined shows fibro collagenous tissue, inflammatory cells(lymphocytes, polymorphs ,plasma cells, blood vessels. Section also shows squamous lining epithelium with round nucleus, macrophages and multinucleated giant cells.

No granuloma and no malignant cells seen.

Note : All biopsy specimen will be stored for 15 (fifteen)days, block and slides for 5(five) years only from the time of receipt at the laboratory. No request ,for any of the above ,will be entertained after the due date.

Reference

- i) Rosai and Ackerman's Surgical Pathology.
- ii) Modern Surgical Pathology.

Gulshan Yadav, MD
Consultant Pathologist