

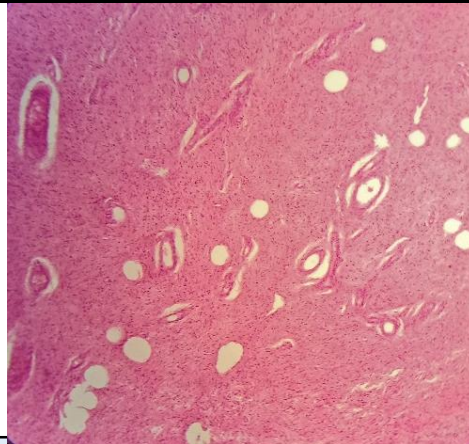
Patient Name	Miss. SNEHA YADAV	Client Name	Lifeaid Wellness Centre	Specimen Received	24/08/2019
Age/Sex	17 Years/Female			Specimen Type	Tissue
Patient ID	011908240328			Collection Date	24/08/2019
Specimen ID	MOLQ/B-1623/19			Report Date	30/08/2019

SURGICAL PATHOLOGY REPORT

Inflamed large nodular swelling back.

DIAGNOSIS

Benign mesenchymal lesion.



SPECIMEN

Inflamed large nodular swelling back.

GROSS

GROSS

Received 1.1x1.3cm grayish white tissue piece.


Microscopy

Microscopy

Section examined shows squamous lining epithelium with round nucleus and glands, fibrocollagenous tissue in bundles with plump oval nucleus with large number of blood vessels.

Reference

- Rosai and Ackerman's Surgical Pathology.
- Modern Surgical Pathology.



Gulshan Yadav, MD
Consultant Pathologist