

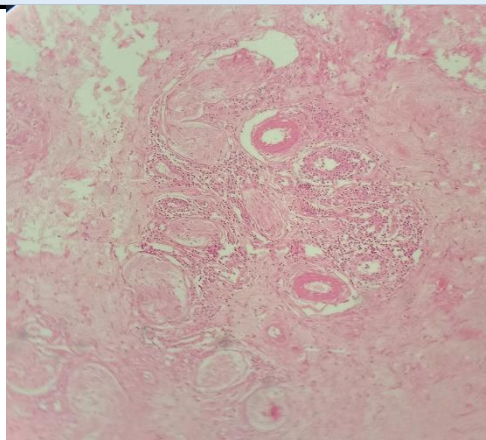
Patient Name	Mr. JAGBIR	Client Name	Path Star Diagnostic	Specimen Received	24/08/2019
Age/Sex	54 Years/Male			Specimen Type	Tissue
Patient ID	011908240212			Collection Date	24/08/2019
Specimen ID	MOLQ/B-1619/19			Report Date	30/08/2019

SURGICAL PATHOLOGY REPORT

Left scrotal swelling.

DIAGNOSIS

Non specific inflammation.



SPECIMEN

Left scrotal swelling.

GROSS

Received multiple grayish white tissue piece, 3.7x3.2 cm in aggregate cut section shows necrotic material.

Microscopy

Section examined shows squamous lining epithelium with round nucleus, fibro collagenous tissue, hair follicle, glands, plasmacytoid cells, mature adipose cells.

Note : All biopsy specimen will be stored for 15 (fifteen) days, block and slides for 5 (five) years only from the time of receipt at the laboratory. No request, for any of the above, will be entertained after the due date.

Reference

- i) Rosai and Ackerman's Surgical Pathology.
- ii) Modern Surgical Pathology.

Gulshan Yadav, MD
Consultant Pathologist