

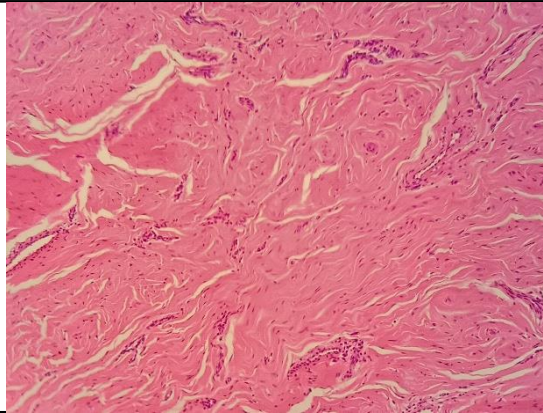
Patient Name	Ms. POOJA	Client Name	Life Care Path Lab, Tauru	Specimen Received	24-08-2019
Age/Sex	24 Years/Female			Specimen Type	Tissue
Patient ID	011908240141			Collection Date	24-08-2019
Specimen ID	MOLQ/B-1617/19			Report Date	29 08 2019

SURGICAL PATHOLOGY REPORT

Gall Bladder

DIAGNOSIS

CHOLECYSTITIS AND CHOLELITHIASIS.



SPECIMEN

Gall Bladder

GROSS

Received 9.4x3.3 cm long gall bladder already cut open with stones.

Microscopy

Section examined shows ulcerative mucosa and Rokitansky-Aschoff sinuses (irregularly shaped tubular structures lined by cuboidal lining epithelium with round to oval nucleus) with fibrocollagenous tissue and inflammatory cells (lymphocytes).

Note : All biopsy specimen will be stored for 15 (fifteen) days, block and slides for 5 (five) years only from the time of receipt at the laboratory. No request, for any of the above, will be entertained after the due date.

Reference

- i) Rosai and Ackerman's Surgical Pathology.
- ii) Modern Surgical Pathology.

Gulshan Yadav, MD
Consultant Pathologist