

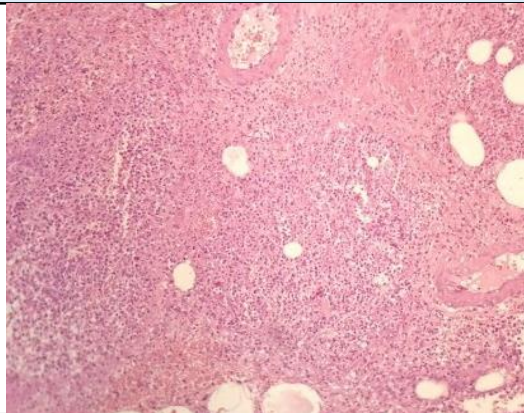
Patient Name	Mr. LAXMAN	Client Name	Accurate Path (C), Agra	Specimen Received	23-08-2019
Age/Sex	18 Years/Male			Specimen Type	Tissue
Patient ID	011908230068			Collection Date	23-08-2019
Specimen ID	MOLQ/B-1611/19			Report Date	29 08 2019

SURGICAL PATHOLOGY REPORT

Appendix

DIAGNOSIS

ACUTE APPENDICITIS



SPECIMEN

Appendix

GROSS

Received 5x1.5cm long appendix. Cut section shows feco-lith.

Microscopy

Section examined shows lymphoid follicles with ulcerative mucosa. Deeper tissue shows inflammatory cells (polymorphs and lymphocytes). No granuloma seen. No malignant cells seen.

Note : All biopsy specimen will be stored for 15 (fifteen)days, block and slides for 5(five) years only from the time of receipt at the laboratory. No request ,for any of the above ,will be entertained after the due date.

Reference

- i) Rosai and Ackerman's Surgical Pathology.
- ii) Modern Surgical Pathology.

Gulshan Yadav, MD
Consultant Pathologist