

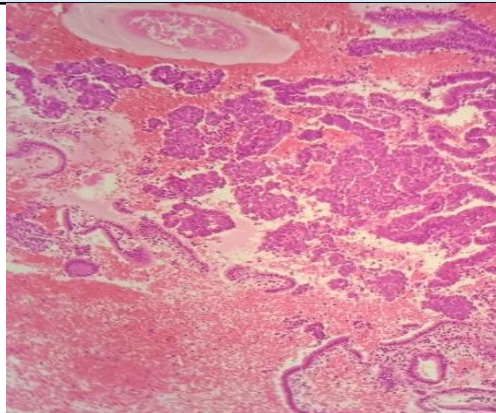
Patient Name	Mrs MINU	Client Name	SRD Path Lab, Palwal	Specimen Received	22-08-2019
Age/Sex	36 YRS/F			Specimen Type	Tissue
Patient ID	011908220332			Collection Date	22-08-2019
Specimen ID	MOLQ/B-1605/19			Report Date	29 08 2019

SURGICAL PATHOLOGY REPORT

Endometrium

DIAGNOSIS

PROLIFERATIVE PHASE WITH SIMPLE HYPERPLASIA WITHOUT ATYPIA.



SPECIMEN

Endometrium

GROSS

Received multiple grayish white tissue piece.

Microscopy

Section examined shows small endometrial glands with cuboidal lining with small round nucleus. Stroma shows mononuclear inflammatory cells. Few glands shows cystically dilated. No granuloma seen. No malignant cells seen.

Note : All biopsy specimen will be stored for 15 (fifteen) days, block and slides for 5 (five) years only from the time of receipt at the laboratory. No request, for any of the above, will be entertained after the due date.

Reference

- i) Rosai and Ackerman's Surgical Pathology.
- ii) Modern Surgical Pathology.

**Gulshan Yadav, MD
Consultant Pathologist**