

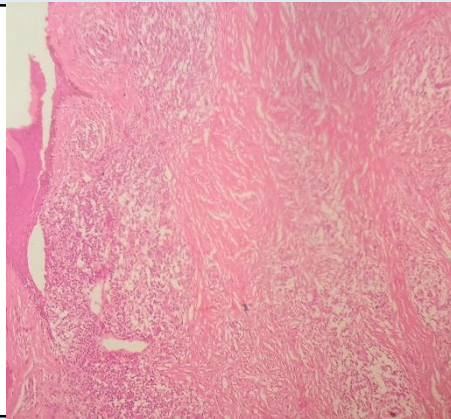
Patient Name	Mr. ISHWAR LAL	Client Name	Pushpanjali Hospital (Rewari)	Specimen Received	22-08-2019
Age/Sex	59 Years/Male			Specimen Type	Tissue
Patient ID	011908220327			Collection Date	22-08-2019
Specimen ID	MOLQ/B-1605/19			Report Date	29 08 2019

SURGICAL PATHOLOGY REPORT

Dermoid cyst.

DIAGNOSIS

Benign mesenchymal lesion



SPECIMEN

Dermoid cyst.

GROSS

Received 2.4x1.9cm grayish white tissue piece

Microscopy

Section examined shows large number of fibro collagenous tissue, blood vessels.
No granuloma and no malignant cells seen.

Note : All biopsy specimen will be stored for 15 (fifteen)days, block and slides for 5(five) years only from the time of receipt at the laboratory. No request ,for any of the above ,will be entertained after the due date.

Reference

- i) Rosai and Ackerman's Surgical Pathology.
- ii) Modern Surgical Pathology.

Gulshan Yadav, MD
Consultant Pathologist