

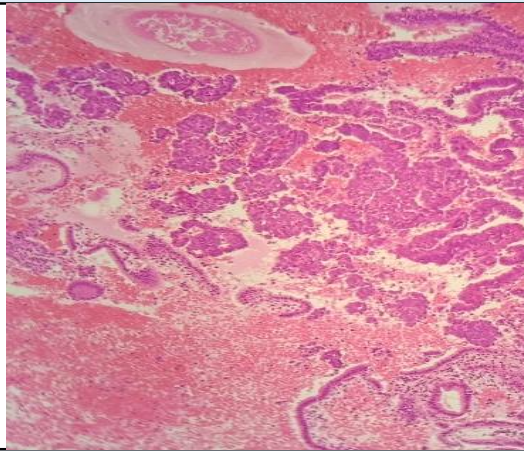
| | | | | | |
|---------------------|-----------------|--------------------|----------------------|--------------------------|------------|
| Patient Name | Mrs. MILY | Client Name | Path Star Diagnostic | Specimen Received | 22/08/2019 |
| Age/Sex | 39 Years/Female | | | Specimen Type | Tissue |
| Patient ID | 011908220224 | | | Collection Date | 22/08/2019 |
| Specimen ID | MOLQ/B-1603/19 | | | Report Date | 28/08/2019 |

SURGICAL PATHOLOGY REPORT

Endometrium

DIAGNOSIS

Disordered proliferative phase



SPECIMEN

Endometrium

GROSS

Received multiple grayish white tissue piece.

Microscopy

Section examined shows small and tortuous endometrial glands with columnar lining epithelium with round to oval nucleus.

Stroma shows mono nuclear inflammatory cells.

Note : All biopsy specimen will be stored for 15 (fifteen)days, block and slides for 5(five) years only from the time of receipt at the laboratory. No request ,for any of the above ,will be entertained after the due date.

Reference

- i) Rosai and Ackerman's Surgical Pathology.
- ii) Modern Surgical Pathology.

Gulshan Yadav, MD
Consultant Pathologist