

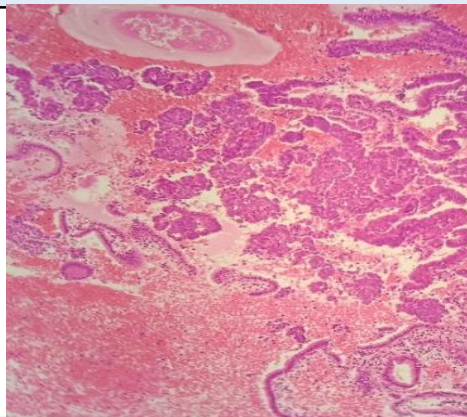
Patient Name	Mrs. DEEPIKA	Client Name	Lifeaid Wellness Centre.	Specimen Received	22/08/2019
Age/Sex	47 Years/Female			Specimen Type	Tissue
Patient ID	011908220174			Collection Date	22/08/2019
Specimen ID	MOLQ/B-1601/19			Report Date	28/08/2019

SURGICAL PATHOLOGY REPORT

Endometrium

DIAGNOSIS

Simple hyperplasia without atypia.



SPECIMEN

Endometrium

GROSS

Received multiple grayish white tissue piece.

Microscopy

Section examined shows small and tortuous and dilated endometrial glands with columnar lining epithelium. Stroma shows mononuclear inflammatory cells seen.

Note : All biopsy specimen will be stored for 15 (fifteen)days, block and slides for 5(five) years only from the time of receipt at the laboratory. No request ,for any of the above ,will be entertained after the due date.

Reference

- i) Rosai and Ackerman's Surgical Pathology.
- ii) Modern Surgical Pathology.

A handwritten signature in black ink, appearing to read 'Gulshan', written over a light blue rectangular background.

Gulshan Yadav, MD
Consultant Pathologist