

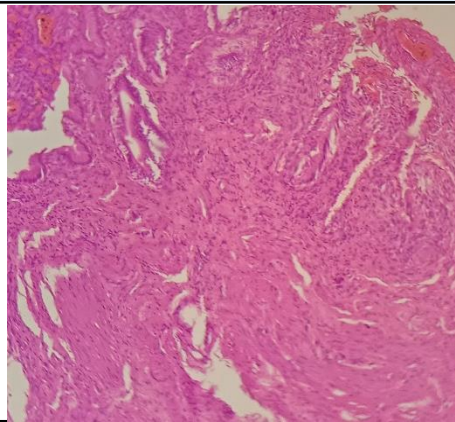
Patient Name	Mrs. RAMWATI	Client Name	Life Care Path Lab, Tauru	Specimen Received	22/08/19
Age/Sex	60 Years/Female			Specimen Type	Tissue
Patient ID	011908220211			Collection Date	22/08/19
Specimen ID	MOLQ/B-1599/19			Report Date	27/08/19

SURGICAL PATHOLOGY REPORT

Gall Bladder

DIAGNOSIS

CHOLECYSTITIS .



SPECIMEN

Gall Bladder

GROSS

Received 7x3cm long gall bladder already cut open no stones.


Microscopy

Section examined shows ulcerative mucosa and Rokitansky Aschoff sinuses (irregularly shaped tubular structures lined by cuboidal lining epithelium with round to oval nucleus) with fibro collagenous tissue and inflammatory cells (lymphocytes).

Note : All biopsy specimen will be stored for 15 (fifteen) days, block and slides for 5 (five) years only from the time of receipt at the laboratory. No request, for any of the above, will be entertained after the due date.

Reference

- i) Rosai and Ackerman's Surgical Pathology.
- ii) Modern Surgical Pathology.


Gulshan Yadav, MD
Consultant Pathologist