

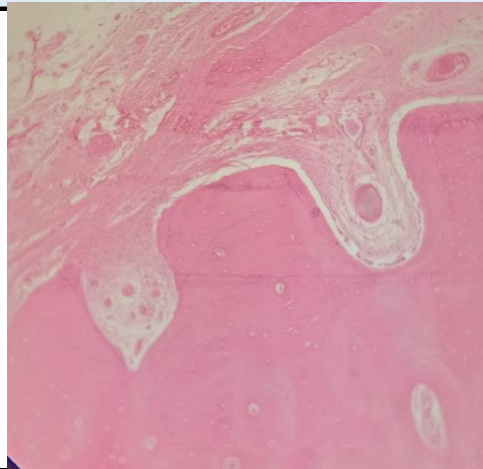
| | | | | | |
|---------------------|------------------------|--------------------|----------------------------------|--------------------------|-------------|
| Patient Name | Mr. MANOJ 35874 | Client Name | Pushpanjali Hospital (Rewari) | Specimen Received | 07-Aug-2019 |
| Age/Sex | 19 Years/Male | | | Specimen Type | Tissue |
| Patient ID | 011908070338 | | | Collection Date | 07-Aug-2019 |
| Specimen ID | MOLQ/B-1514/19 | | | Report Date | 26-Aug-2019 |

SURGICAL PATHOLOGY REPORT

Right fibula bone

DIAGNOSIS

Chronic Osteomyelitis



SPECIMEN

Right fibula bone

GROSS

Received 6.8x3.4cm bony piece.

Microscopy

- Section examined shows bony trabeculae with marrow fats and cells with sequestrum, predominantly lymphocytes and histiocytes, areas of necrosis.

Note : All biopsy specimen will be stored for 15 (fifteen)days, block and slides for 5(five) years only from the time of receipt at the laboratory. No request ,for any of the above ,will be entertained after the due date.

Reference

- Rosai and Ackerman's Surgical Pathology.
- Modern Surgical Pathology.

Gulshan Yadav, MD
Consultant Pathologist