

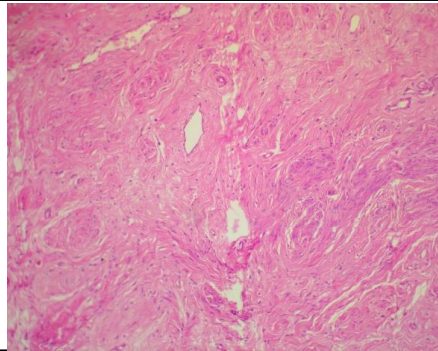
Patient Name	Mrs. SAROJ	Client Name	Pushpanjali Hospital (Rewari)	Specimen Received	21-Aug-2019
Age/Sex	52 Years/Female	Client Code	MolQ1789CM	Specimen Type	Tissue
Patient ID	011908210304	Ref. Doctor		Collection Date	21-Aug-2019
Specimen ID	MOLQ/B-1590/19			Report Date	26-Aug-2019

SURGICAL PATHOLOGY REPORT

Uterus with Cervix

DIAGNOSIS

Leiomyoma



SPECIMEN

Uterus with Cervix

GROSS

Received 8x5 cm uterus with cervix with bilateral tubes with paratubal cyst measuring 4.5x3.2cm, 2.5x2.1cm cut section shows multiple fibroid measuring 1x1, 0.5x0.5cm.

Microscopy

Section examined shows

- 1) Endometrium with proliferative phase
 - 2) Myometrium with muscle bundles
 - 3) Cervix with mononuclear inflammatory cells
 - 4) Fibroid with interlacing muscle bundles.
 - 4) Tube unremarkable and cyst shows columnar lining epithelium with round nucleus.
 - 5) Other tubes unremarkable and paratubal cyst shows squamous lining epithelium.
1. **Note** : All biopsy specimen will be stored for 15 (fifteen) days, block and slides for 5 (five) years only from the time of receipt at the laboratory. No request, for any of the above, will be entertained after the due date.

Reference

- i) Rosai and Ackerman's Surgical Pathology.
- ii) Modern Surgical Pathology.

Gulshan Yadav, MD
Consultant Pathologist