

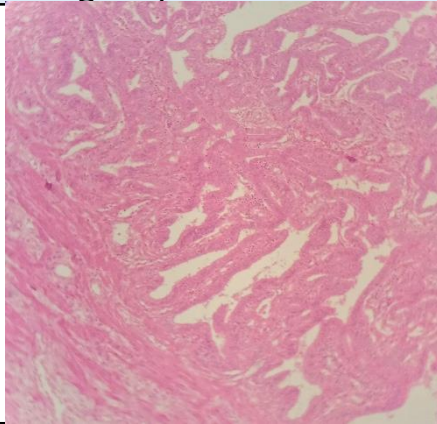
Patient Name	Mrs. SULTANA	Client Name	Path Star DiagnosticClient	Specimen Received	20/08/19
Age/Sex	23 Years/Female			Specimen Type	Tissue
Patient ID	011908200175			Collection Date	20/08/19
Specimen ID	MOLQ/B-1585/19(1)			Report Date	26/08/19

SURGICAL PATHOLOGY REPORT

Tube

DIAGNOSIS

In view of no trophoblastic cells in the lumen kindly Co-relate with radiologically.



SPECIMEN

Tube

GROSS

Received 4x2.4 grayish white tissue piece.


Microscopy

Section examined shows tubal lining epithelium with surrounding tissue with RBCs in the lumen no trophoblastic cells and no villi seen.

Note : All biopsy specimen will be stored for 15 (fifteen)days, block and slides for 5(five) years only from the time of receipt at the laboratory. No request ,for any of the above ,will be entertained after the due date.

Reference

- i) Rosai and Ackerman's Surgical Pathology.
- ii) Modern Surgical Pathology.


Gulshan Yadav, MD
Consultant Pathologist