

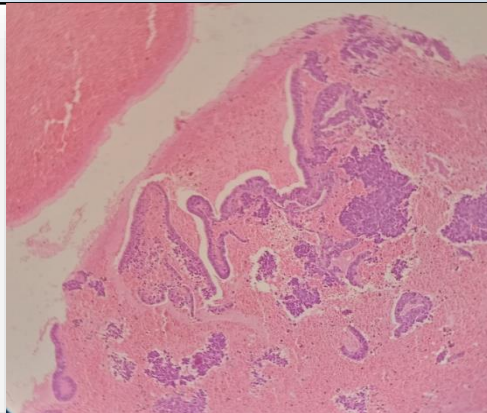
Patient Name	Mrs. URMILA	Client Name	Pushpanjali Hospital (Rewari)	Specimen Received	19/08/2019
Age/Sex	40 Years/Female			Specimen Type	Tissue
Patient ID	011908190318			Collection Date	19/08/2019
Specimen ID	MOLQ/B-1578/19			Report Date	24/08/2019

SURGICAL PATHOLOGY REPORT

Endometrium

DIAGNOSIS

PROLIFERATIVE PHASE



SPECIMEN

Endometrium

GROSS

Received multiple grayish white tissue piece.

Microscopy

Section examined shows small endometrial glands with cuboidal lining with small round nucleus. Stroma shows mononuclear inflammatory cells.

No granuloma seen. No malignant cells seen.

Note : All biopsy specimen will be stored for 15 (fifteen) days, block and slides for 5 (five) years only from the time of receipt at the laboratory. No request, for any of the above, will be entertained after the due date.

Reference

- i) Rosai and Ackerman's Surgical Pathology.
- ii) Modern Surgical Pathology.

A handwritten signature in black ink, appearing to read 'Gulshan', written over a light blue rectangular background.

Gulshan Yadav, MD
Consultant Pathologist