

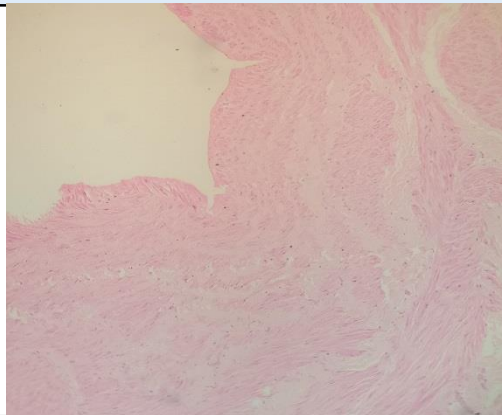
Patient Name	Mrs. BABITA-36743	Client Name Pushpanjali Hospital (Rewari)	Specimen Received	18/08/2019
Age/Sex	25 Years/Female		Specimen Type	Tissue
Patient ID	011908180217		Collection Date	18/08/2019
Specimen ID	MOLQ/B-1575/19		Report Date	24/08/2019

SURGICAL PATHOLOGY REPORT

Left great saphenous vein

DIAGNOSIS

Varicose vain.



SPECIMEN

Left great saphenous vein

GROSS

Received 12.5x0.4cm grayish white tissue piece.


Microscopy

Section examined shows dilated vein wall with fibro collagenous tissue and surrounding tissue piece.

Note : All biopsy specimen will be stored for 15 (fifteen)days, block and slides for 5(five) years only from the time of receipt at the laboratory. No request ,for any of the above ,will be entertained after the due date.

Reference

- i) Rosai and Ackerman's Surgical Pathology.
- ii) Modern Surgical Pathology.



Gulshan Yadav, MD
Consultant Pathologist